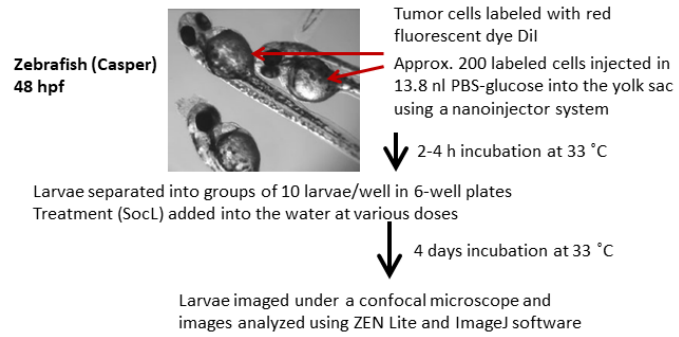


Supplementary Material 1

Table 1S. Antibodies and Signaling Inhibitors 3

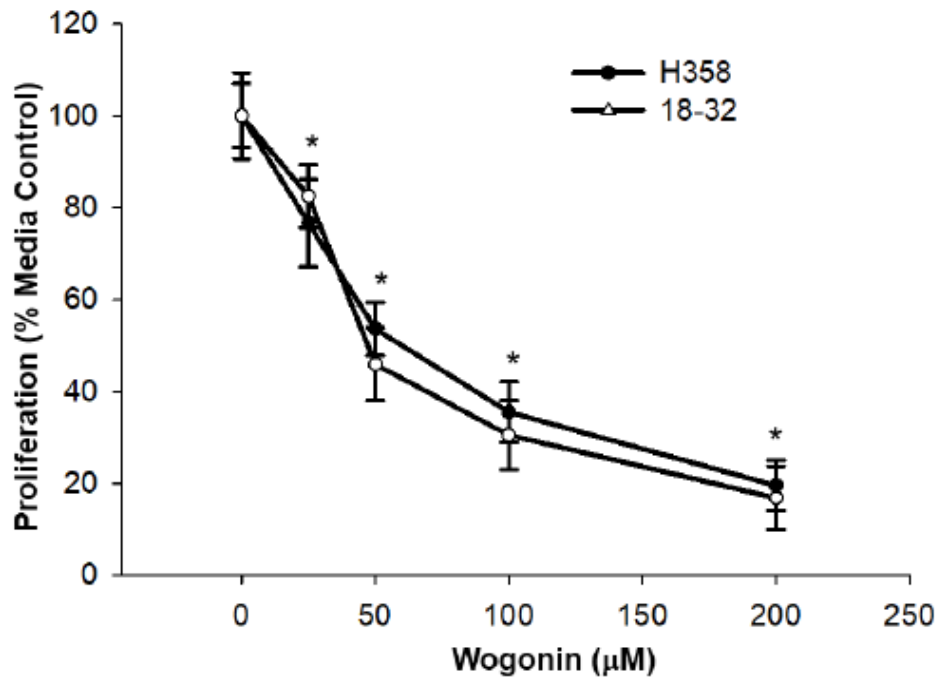
Manufacturer	Antibody/Inhibitor	Catalog #
Thermo-fisher	B-Actin, HRP conjugated	MA5-15739
Cell signaling	AKT	#9279
Cell Signaling	P-Akt(S473)	#4060P
Cell Signaling	P44/42 Map Kinase	#9102
Cell Signaling	P-P44/42 Map Kinase	#9101
Cell Signaling	P38 Map Kinase	#9212
Cell Signaling	P-P38 Map Kinase (T180/Y182)(12F8)	#4631P
Cell Signaling	Bcl-2(50E3)	#2870S
Cell Signaling	Bcl-xL(54H6)	#2764
Thermo-Scientific	Goat Anti-Rabbit HRP	#31460
Cell Signaling	MMP-2	#4022
R & D Systems	P38 inhibitor	SB202190

Supplementary Data, Fig. S1. The zebrafish xenotransplant model for human NSCLC



Supplementary Data:

Figure 2S. Wogonin dose-dependently inhibits the proliferation of non-small cell lung cancer (NSCLC) cells.



NSCLC cell line (H358) and patient-derived, brain metastatic NSCLC cells (18-032) were cultured with various doses of wogonin, as indicated. After 72 hours of culture, a WST-1 assay was performed to estimate cell proliferation/viability as described under the methods. Data are mean \pm SD of three different experiments. * $p < 0.05$ versus media controls.

Cell Line 18-032

*** Final Report ***

(Age: 69) Gender: F

AP SPECIMEN DESCRIPTION

Karmanos Cancer Center

4100 John R

Detroit, Michigan 48201

Tel: 313-745-8555 Fax: 313-966-8989

Surgical Pathology Report

Ordering Phy: SANDEEP MITTAL

=====

FINAL PATHOLOGIC DIAGNOSES

Craniotomy for resection of left temporo-occipital brain tumor:

- Poorly differentiated metastatic carcinoma, with extensive necrosis, in brain (please see comment).

PATHOLOGIC STAGE AND CASE SUMMARY

COMMENT

Permanent sections confirm frozen section diagnosis. The staining properties are similar to those noted in the previous specimen SKI18-1945 (Left lung guided biopsy: non small cell carcinoma with extensive necrosis). The tumor lacks staining for typical markers associated with lung adenocarcinomas (CK7, TTF-1, napsin), squamous carcinoma (CK 5/6, p40), and neuroendocrine carcinomas (TTF-1, synaptophysin, chromogranin), and shows only sparse focal immunoreactivity for CD56. This finding, however, is not considered sufficient for a definite diagnosis of neuroendocrine carcinoma.

Note: All the slides on this case have been microscopically examined by the signing pathologist, unless indicated as 'Gross only'.

Electronically Signed Out

William J. Kupsky , M.D.

All tests performed by DMC University Laboratories/University Pathologists,P.C.

=====

SPECIMEN(S)

Left temporal occipital lung metastasis permanent/frozen

PROCEDURE

Craniotomy stereotactic tumor

PREOPERATIVE DIAGNOSIS

Left temporo occipital brain tumor

POSTOPERATIVE DIAGNOSIS

Same

INTRAOPERATIVE DIAGNOSIS

Frozen section Diagnosis: Largely necrotic carcinoma

Pt. ID checked: Yes

Number of FS Blocks: One

Report to Dr. Mittal by Dr Kupsky

GROSS DESCRIPTION

Received fresh for frozen section labeled left temporal occipital lung metastasis and consists of multiple fragments of necrotic, pink-tan soft tissue, aggregating to 2.5 x 2.0 x 0.6 cm. Touch preps were performed for triaging purposes. Representative sections are sent for frozen section. Summary of sections:

Cassette FS1 - frozen section Cassette 2 -3-all remaining tissue

MICROSCOPIC DESCRIPTION

Sections show pieces of cerebral cortex and white matter invaded by extensively necrotic carcinoma. The tumor consists of irregular nests and clusters of moderately large pleomorphic cells, often forming perivascular columnar basaloid arrays of cells. The cells have large nuclei, often with multiple nucleoli, and moderate amounts of cytoplasm. Numerous, often atypical mitotic figures and frequent apoptotic cells are present. Blood vessels are often occluded by fibrin thrombi. Small numbers of tumor cells are immunoreactive for CD56, and very rare tumor cell nuclei are reactive for p40. No staining is noted for CK7, CK5/6, TTF-1, napsin, synaptophysin, or chromogranin.

This test was developed and its performance and characteristics determined by the DMC University Laboratories. It has not been cleared or approved by the U.S. Food and Drug Administration (FDA). The FDA has determined that such clearance or approval is not necessary. This test is used for clinical purposes. It should not be regarded as investigational or for research. This laboratory is certified under the Clinical Laboratory Improvement Amendments of 1988 (CLIA-88) as qualified to perform high complexity clinical laboratory testing.

Cell Line 18-033

* Final Report *

(Age: 60) Gender: F

AP SPECIMEN DESCRIPTION

Harper University Hospital

Department of Pathology

3990 John R

Detroit, MI 48201

Tel: 313-745-8555 Fax: 313-966-8989

Surgical Pathology Report

Ordering Phy: SANDEEP MITTAL

=====

FINAL PATHOLOGIC DIAGNOSES

Craniotomy for resection of left frontal tumor:

- Metastatic poorly differentiated carcinoma, with squamous features, in brain (See comment).

PATHOLOGIC STAGE AND CASE SUMMARY

COMMENT

The permanent sections confirm the frozen section diagnosis. The tumor features are compatible with tumor seen in previous specimen SH18-1452 (CT guided needle core biopsy of left lung mass, non-small cell carcinoma, immunohistochemical features consistent with squamous cell carcinoma).

Note: All the slides on this case have been microscopically examined by the signing pathologist, unless indicated as 'Gross only'.

Electronically Signed Out

William J. Kupsky , M.D.

=====

SPECIMEN(S)

Left frontal lung metastasis frozen / permanent

PROCEDURE

Left frontal craniotomy for tumor resection

PREOPERATIVE DIAGNOSIS

Lung metastasis

POSTOPERATIVE DIAGNOSIS

Same

INTRAOPERATIVE DIAGNOSIS

Frozen section Diagnosis: Carcinoma.

Pt. ID checked: Yes

Number of FS Blocks: 1

Report to Dr. Mittal by Dr. Kupsky

GROSS DESCRIPTION

Received fresh for frozen with patient identifiers and labeled as "left frontal lung metastasis" consisting of an irregular piece of soft tissue measuring 2 x 1.8 x 0.7 cm. There is a separate irregular piece measuring 0.6 x 0.4 x 0.2 cm. The specimen is serially sectioned and smears performed. A representative section is submitted for frozen.

Entire specimen is submitted in three cassettes.

Cassette FS: Representative sections submitted for frozen.

Cassette 2- 3: Reminder of tissue.

MICROSCOPIC DESCRIPTION

Sections show pieces of poorly differentiated carcinoma invading reactive brain tissue containing proliferating reactive blood vessels, reactive astrocytes, and sparse lymphocytic infiltration. The tumor consists of nests of pleomorphic polygonal cells with big hyperchromatic nuclei, distinct nucleoli, and variable amounts of cytoplasm, including clusters of larger keratinized cells. Frequent mitotic figures and occasional small foci of necrosis are noted.