




University of  
Massachusetts  
Amherst

## **A study of the effects of lesions of the ventromedial hypothalamus in the mongolian gerbil, *Meriones unguiculatus*.**

Item Type	Thesis (Open Access)
Authors	Koenig, Allen Benfield
DOI	<a href="https://doi.org/10.7275/ksbv-9r90">10.7275/ksbv-9r90</a>
Download date	2026-06-10 12:01:14
Link to Item	<a href="https://hdl.handle.net/20.500.14394/45167">https://hdl.handle.net/20.500.14394/45167</a>

UMASS/AMHERST



312066013802058



A STUDY OF THE EFFECTS OF LESIONS OF  
THE VENTROMEDIAL HYPOTHALAMUS IN THE  
MONGOLIAN GERBIL, MERIONES UNGUICULATUS.

A Thesis Presented

By

ALLEN BENFIELD KOENIG

Submitted to the Graduate School of the  
University of Massachusetts in partial  
fulfillment of the requirements for the degree of

MASTER OF SCIENCE

August

1973

Major Subject Psychology


A STUDY OF THE EFFECTS OF LESIONS OF  
THE VENTROMEDIAL HYPOTHALAMUS IN THE  
MONGOLIAN GERBIL, MERIONES UNGUICULATUS.

A Thesis


By

ALLEN BENFIELD KOENIG


Approved as to style and content by:




Dr. Saul Balagura



Dr. Richard T. Loutitt



Dr. John Donahoe



Dr. Paul Wade

August

1973

### Acknowledgements

This work was partially supported by NIMH Training Grant MH-11823. My personal thanks to Dr. George Wolf, Dr. E.E. Kriekhaus and Ms. Fay Gomes for technical and scientific assistance in neuroanatomy.

### Abstract

Mongolian Gerbils with lesions in the ventromedial hypothalamus show two major similarities with rats lesioned in the same area: an unusually long meal soon after surgery (acute dynamic period), and changes in day-night feeding patterns (chronic dynamic period). They do not share the hypoactive and ragic behavior of the ventromedial hypothalamically-lesioned rat. Tests and observations showed little or no difference between the general demeanor of lesioned and normal animals.

## List of Figures

Figure 1	Drinkometer Schematic	Page 5
2	Histology	10
3	Typical Acute Dynamic Phase Records	12
4	Graph of Pre- and Post-Lesion Meal Frequencies	14

An early milestone in the study of neuroregulatory phenomena was the discovery by Hetherington and Ranson (1939) that lesions of the ventromedial hypothalamus lead to obesity. In 1946, Brobeck published evidence showing that such obesity was due to hyperphagia. Anand and Brobeck (1951) demonstrated that lesions of the adjacent lateral hypothalamus produce the opposite effect, aphagia and resultant loss of weight. These and other investigations have implicated the diencephalon as a regulatory center for the body's "internal milieu."

Although most studies of the results of lateral hypothalamic and ventromedial hypothalamic lesions have been done on the rat, there has been supporting evidence obtained in other species, such as rabbits (Romaniuk, 1962), dogs (Fonberg, 1969), cats (Stevenson and Montemurro, 1952; Anand, Dua and Schoenberg, 1955), monkeys (Hetherington, 1944; Anand, Dua and Schoenberg, 1955) and humans (Reeves and Plum, 1969). The remarkable neuroanatomical similarity of all mammalian species (excluding acallosal forms) and the similarity of these findings certainly suggests that certain areas of the brain may serve similar functions in different mammalian species.

Given a lesion approach to the study of functional neuroanatomy, it is obviously important to make as detailed an analysis as possible of pre- versus post-lesion behavior.

Brooks (1946) was the first to take this approach with ventromedial hypothalamically lesioned animals. By measuring the amount of food consumed by his animals every twelve hours, he discovered that lesioned rats increased their daylight food intake substantially. A finer analysis of such post-lesion changes in eating behavior was done by Balagura and Devenport (1970), who discovered two distinct phases of meal eating following ventromedial hypothalamic lesions, the acute and the chronic dynamic periods. The acute dynamic period occurs immediately upon the awakening of the rat from surgery, and consists of an unusually long uninterrupted spell of eating. The chronic dynamic period begins once the eating behavior of the rat has resolved into discrete but frequent meals.

Animals with lesions of the ventromedial hypothalamus are generally hyperemotional, ragic and hypoactive. This phenomenon has been observed in rats (Grossman, 1972), cats (Wheatley, 1944) and humans (Reeves and Plum, 1969).

I have chosen to study the effects of ventromedial hypothalamic lesions in another species of mammal, the Mongolian Gerbil (Meriones unguiculatus), with particular attention to the fine analysis of feeding patterns and the effect of such lesions on emotionality and activity. The Mongolian Gerbil has many qualities that make it a good experimental species. They are very friendly, odorless

and hardy, these abilities greatly simplifying the normal maintenance and handling procedures in research. Being natives of the arid Mongolian Desert, their environment is very different from that of the laboratory rat and other commonly used laboratory animals. This provides an opportunity not only to collect data on a new species, but also to compare the effects of similar experimental manipulations on species having different survival needs, this leading either to a sharper delineation of species-specific effects, or to a strengthening of cross-species effect-generality.

### Methods

Twenty-three male Mongolian Gerbils (Meriones unguiculatus) ninety to 120 days old were used as experimental subjects. The animals were obtained from Tumblebrook Farm (West Brookfield, Mass.) or were bred from the same stock. All animals were housed in large cages (six per cage) on a twelve hour light-dark cycle (light on at 7 a.m.), and were maintained on ad libitum Purina rat chow and water until two weeks before surgery.

Two weeks before surgery the animals were transferred to experimental chambers, where they remained for the duration of the study. The chambers, 7 x 14 x 8 inches high, had a Plexiglass front equipped with two graduated drinking

bottles (100 ml capacity), wire mesh floor and lid, and plywood rear wall and sides.

Once in the testing chamber an animal was maintained on water and a complete liquid diet (Similac concentrate, Ross Laboratories) mixed one-to-one with water. Ten milliliters of 0.027% saccharin solution per fluid ounce of mixture was added to increase palatability. The drinking tubes were washed and refilled daily, at which time measurements of liquid diet and water consumption were recorded.

Determination of feeding patterns. A solid-state drinkometer connected to the bottle containing the liquid diet actuated a pen on an Esterline-Angus chart recorder. The drinkometer circuit used is shown diagrammatically (Figure 1) for it represents an inexpensive, simple, sensitive, reliable and compact unit easy to build and use. In order to assure a better contact between the cage floor and the gerbil, it was necessary to apply a hair removing cream to the feet.

When a gerbil's intake of Similac had stabilized (in about seven to eight days), continuous monitoring of diet intake was begun. After five days of recording, each animal was removed from its chamber for surgery. Immediately after surgical lesioning the animals were returned to their chambers, where Similac drinking was continuously monitored.

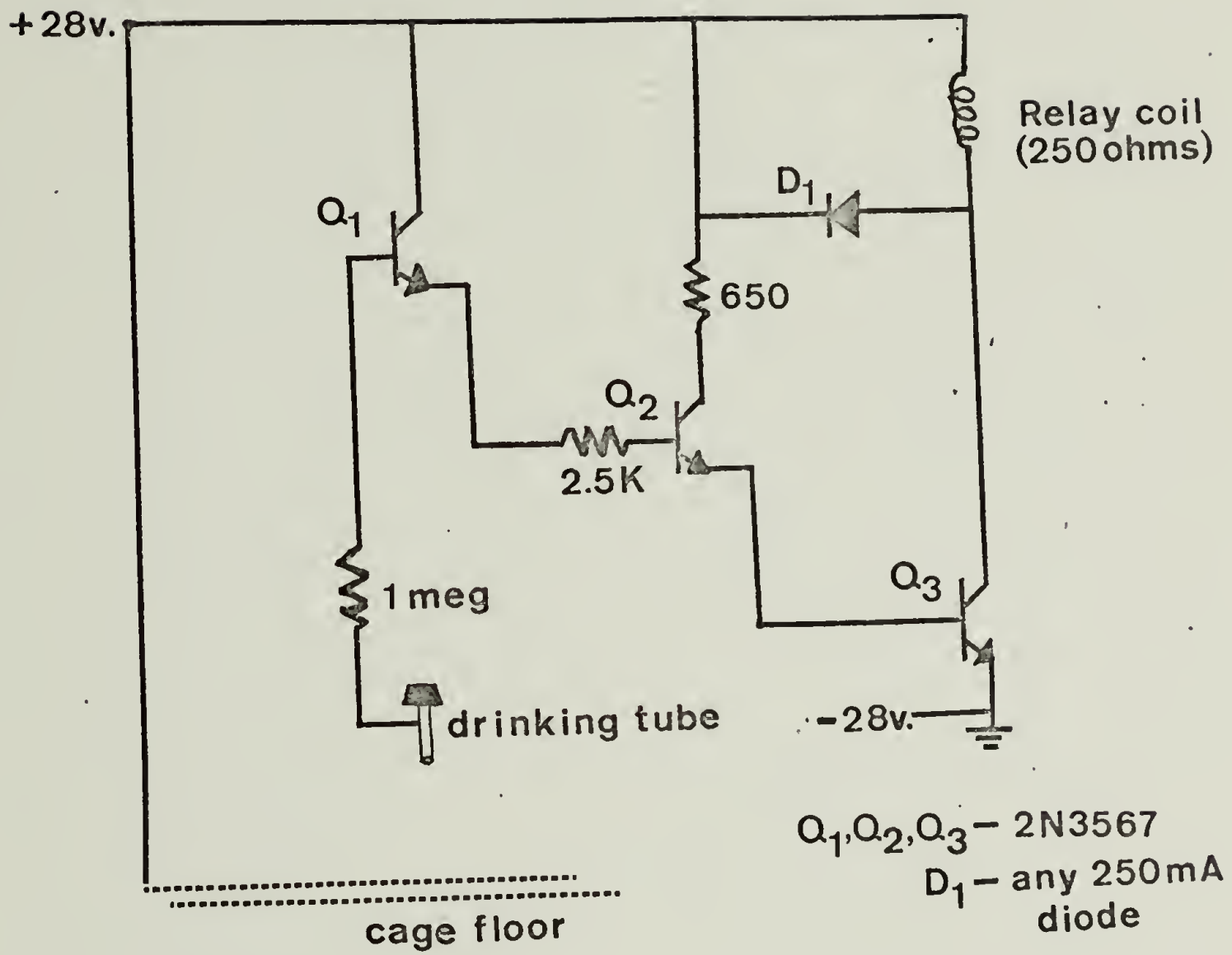


Figure 1

The analysis of the lesion effects on feeding behavior was made as follows: the number of meals and the duration of the intervals between meals during both dark and light periods five days prior to surgery were compared to the corresponding data obtained on the five days that followed surgery. A discrete meal was defined as a period of licking at the liquid diet that lasted at least forty-five seconds and that was preceded by and followed by an inter-meal interval of at least six minutes.

Due to the use of a water-based liquid diet, a test was performed to insure that any post-lesion increase in amount or frequency of consumption was not due merely to the lesion having changed drinking behavior, rather than eating behavior. In this test, two unoperated male gerbils were maintained on ad libitum liquid diet and water for one week. They were then fed exclusively on dry lab chow for four days without water. The gerbils were then presented with graduated bottles of water and liquid diet for one hour, and measures of their consumption during this period were taken. Although the Mongolian Gerbil is extremely efficient at water retention, maintenance on dry lab chow results in thirst and eventual death by dehydration (Reynierse et al, 1970). This test would therefore establish whether a thirsty gerbil would prefer water to liquid diet.

Determination of activity and rage. Measurements of activity and rage were made one day before and five days after surgery. Activity level was tested in an open field thirty-six inches square with black lines marking out a grid of six inch squares on a white background. The field was illuminated by a fifteen watt bulb suspended at a height of four feet. The animals were taken from their cages, placed in a five by seven inch cylindrical container for thirty seconds and then placed on a corner of the open field. The number of squares crossed and the number of rearings were counted over a two minute period. Rage was tested by poking the animal twice with a pencil on the lateral aspect of the neck. The number of biting responses to the pencil were counted and taken as a measure of rage. Rage reactions were also studied while the animals were handled during the activity measurements. Both activity and rage measurements were made between two and four in the afternoon, during the light period.

Surgery. All animals were anesthetized with a dose of 0.04 ml of Diabotal (60 mg/ml).<sup>1</sup> Next the animals were placed in a Kopf stereotaxic instrument, the skin of the

---

<sup>1</sup>This dose of Diabotal appears to be equally effective for both male and female adult gerbils, regardless of body weight. The Mongolian Gerbil seems to be quite resistant to the respiratory congestion due to anesthetics commonly seen in anesthetized rats.

skull slit and retracted, and a midline midsagittal sinus reading taken immediately. This sinus is visible through the gerbil's skull for only a minute or two, then vanishes when the skull surface is dried by the air. The skull was then horizontally leveled between lambda and bregma, and electrodes were lowered bilaterally into the brain (stainless steel 00 insect pins insulated except at the tip with Teflon). The coordinates were 0.35 mm lateral to midline, 1.2 mm posterior to the anterior edge of bregma, and 7.2 mm below the skull top.<sup>2</sup> Lesions were made by passing 0.5 mA anodal current for one to three seconds.

Histology. In order to minimize the variability of the lesion estimates (Wolf & DiCara, 1969), all the animals were sacrificed five days after surgery with an overdose of Diabutal. They were immediately perfused with saline and ten per cent buffered formalin. Frozen sections of the brain were cut thirty-three microns thick, mounted and stained with cresyl violet.

---

<sup>2</sup>Attempts were made to utilize the hypothalamic atlas of the gerbil by Theissen and Goar (1970), but their coordinates proved to be inaccurate upon repeated test lesioning and histology. Aside from such discrepancies between their coordinates and actual neuroanatomical loci in animals from the same supplier, their atlas has other limitations, such as the lack of any photographs to substantiate their projection drawings, and the lack of agreement between coordinates given for certain hypothalamic structures and coordinates derived from their drawings.

## Results and Discussion

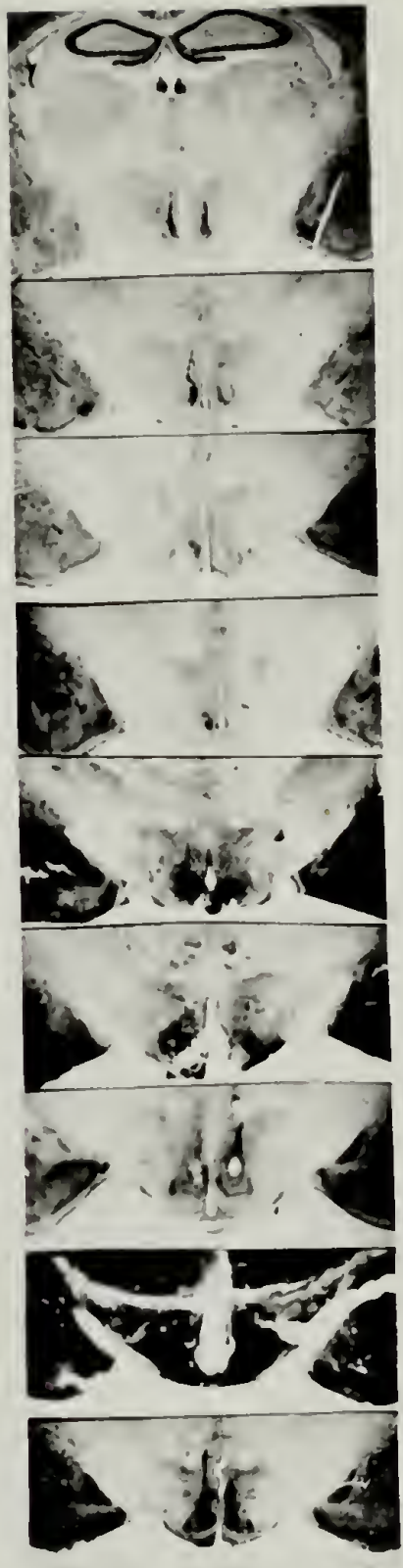
It is interesting to note that diencephalic lesion-current parameters commonly used in rats and mice prove to render gerbils inactive, aphagic and unhealthy. Rather than a reflection of the intolerance of the gerbil to such lesions, I feel that it is a matter of the extreme tolerance of rats and mice to lesions generally much larger than necessary or desirable.

Histology. Twenty-two animals survived the effects of the surgical lesioning. Nine of these sustained 50% or more bilateral damage to the ventromedial hypothalamic nuclei. These animals are called the ventromedial hypothalamic group. In four of these gerbils, damage was confined almost entirely to the ventromedial hypothalamic nuclei. The other ventromedial hypothalamic animals sustained small amounts of damage to the adjacent areas of the dorsal hypothalamic nuclei (n=3) and the periventricular area (n=2). The histology appears in Figure 2.

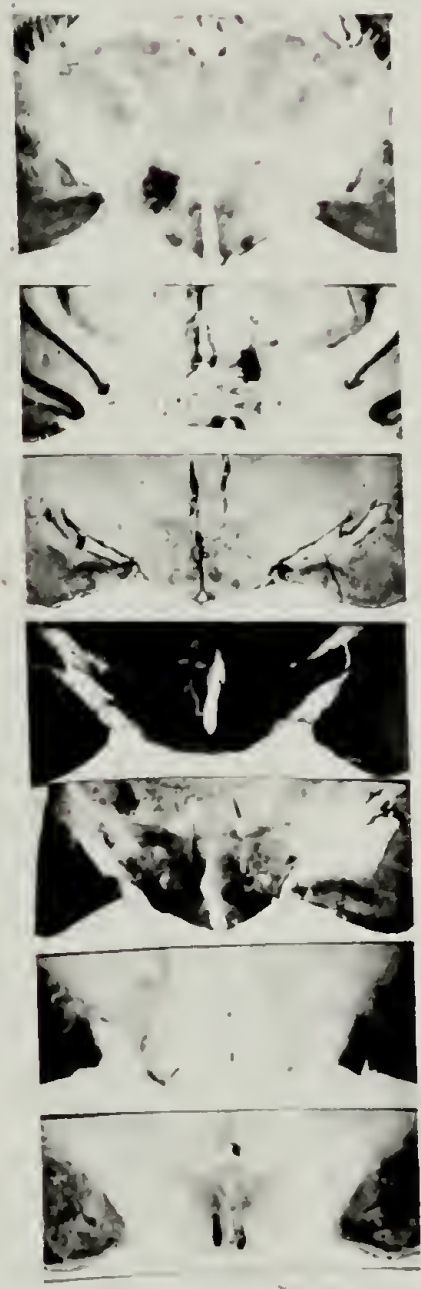
Animals with extra-ventromedial hypothalamic lesions were divided into an anteromedial (n=6) and a posteromedial (n=7) group on the basis of histological examination. The anteromedial lesions occurred as far rostrally as the level of the anterior hypothalamic area. The posteromedial lesions occurred as far caudally as the level of the



ANT.



VMH



POST.

Fig 2

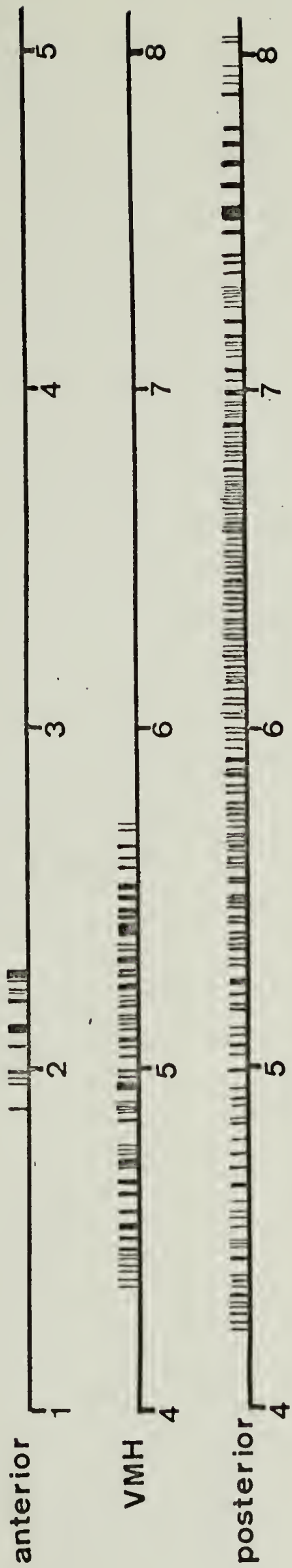
center of the mammillary bodies. Several of these animals (n=5) sustained less than 30% unilateral ventromedial hypothalamic damage. These gerbils served as lesion controls.

Feeding effects: Response to dehydration. After being made thirsty by a diet of dry lab chow, two male gerbils drank an average of 35 ml of water in one hour compared to an average of 2 ml of liquid diet. This substantiates our view that the gerbils' consumption of liquid diet was not due to a change in drinking, but rather in eating behavior.

Acute dynamic period. Upon recovering from surgical anesthesia, most gerbils engaged in a prolonged period of continuous eating of their liquid diet. The average meal length of a normal Mongolian Gerbil is eight minutes. This large meal was of one to 240 minutes in length. The anteromedial lesion control group had a short continuous bout of eating (mean 12.5 minutes). The ventromedial hypothalamic group animals showed an average of forty-seven minutes of continuous eating following surgery; the posteromedial lesion control group ate for an average of 132 minutes on recovering. These results are illustrated in Figure 3. When comparing these records of the acute dynamic period across groups, there is a clear trend for longer bouts of eating during this stage as lesions became more posterior.

Chronic dynamic period. This phase of the ventromedial hypothalamic syndrome begins when the animal re-

Group



time in hours  
after surgery

Figure 3

solves his eating behavior into discrete meals after the long meal of the acute dynamic period. It appears that this phase occurs in the gerbil as well as the rat. Before lesioning, gerbils ate an average of 6.5 meals during the light period. After surgery, gerbils with ventromedial hypothalamic lesions ate an average of 12.3 meals during the same period ( $t=6.244$ ,  $p .001$ ). There was no significant difference between the average number of dark-period meals eaten before and after lesioning (mean of ten before and twelve after). Lesion controls did not show a significant increase in lighttime feeding behavior (an average of 6.1 meals before and 5.8 meals after surgery), but did decrease their darktime eating (11 meals before and 7.5 meals after surgery). I attribute this decrease to a profound darktime feeding depression in two of the animals with large posterior lesions. These results are graphed in Figure 4.

Intermeal intervals before and after lesioning were also compared. There were two effects of statistical significance: the ventromedial hypothalamic group showed a shorter intermeal interval after surgery (222 minutes before and 72 minutes after,  $t=2.02$ ,  $p .05$ ), and the lesion controls showed a longer meal length after surgery during the dark period (95 minutes before and 191 minutes after,  $t=1.93$ ,  $p .05$ ). This last effect is again the result of a

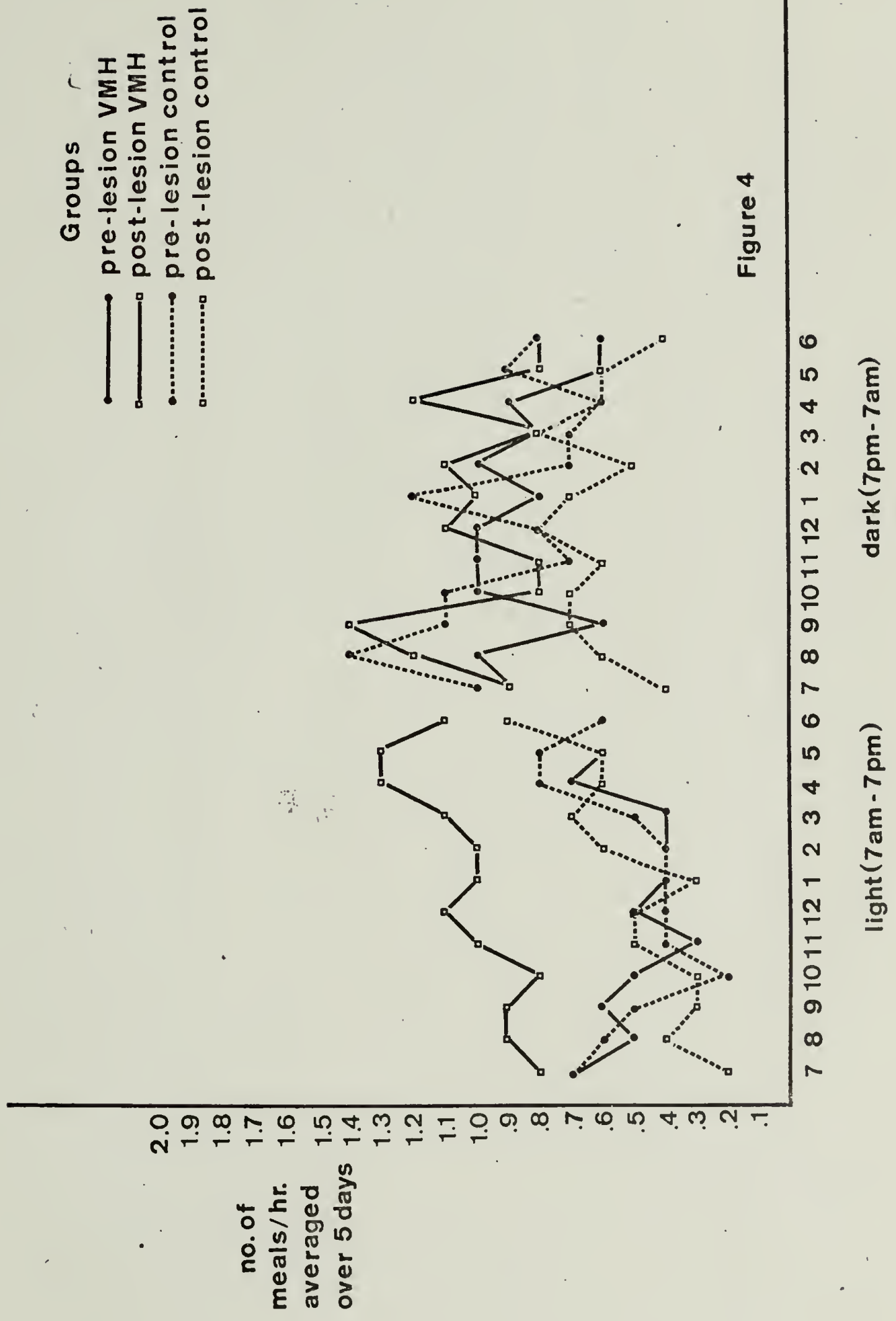


Figure 4

large depression of darktime feeding in two animals with large posterior lesions.

These results are similar to those obtained in rats by Balagura and Devenport (1970), with the exception that gerbils do not increase the frequency of darktime meals after lesioning, while rats do. This may be a species difference, but could also be due to the use of a liquid diet rather than Noyes pellets. The depression in nighttime feeding in the two animals with large posterior lesions was due to their general inactivity and lack of eating behavior.

Changes in intake. None of the three groups significantly changed their total twenty-four hour intake of liquid diet or water after surgery. This result is markedly different from results in other species, where hyperphagia is the rule following ventromedial hypothalamic lesions. The lack of hyperphagia observed could be due to other factors, such as the use of a liquid diet, or the chronic lack of proper thermoregulation in the research facilities available (temperatures often stayed as high as ninety degrees for several days), or it could be due to the species difference. However, similar results were obtained in guinea pigs (Joseph and Knigge, 1968). No post-ventromedial hypothalamic lesion increases in food intake in immature or adult animals were found. It is possible that the

absence of hyperphagia resulted from relatively small lesion size. Most ventromedial hypothalamic lesions done in rats, for example, are fairly large, often involving substantial extra-ventromedial hypothalamic tissue damage. The resolution of this question probably lies in further studies using accurate lesioning techniques.

Activity and rage. The hypoactivity and rage observed in rats after ventromedial hypothalamic lesions was not observed in the Mongolian Gerbil. Prior to lesioning the gerbils had a mean activity level of fifty-seven crosses and ten rearings during the two minute test period. Five days after surgery the ventromedial hypothalamic animals had not modified their activity (an average of sixty crosses and 7.7 rearings per animal). Similarly, gerbils with anteromedial hypothalamic lesions did not alter their activity (sixty-one crosses and 10.8 rearings after surgery). Animals with posteromedial lesions showed a decrease in activity to thirty-five crosses and 6.6 rearings; this, however, was due to the general postoperative hypoactivity of the two animals having the most posterior lesions (at the level of the mammillary bodies).

In no instance was there a biting attack during the poking test either before or after surgery, irrespective of lesion placement. In addition, all animals were easy to handle, never attempted to bite the hand of the experimen-

ter, and except for the two animals with the most posterior lesions, their general demeanor was indistinguishable from that of non-lesioned gerbils.

Summary. Although the environments of the mesic omnivorous rat and the xeric herbivorous Mongolian Gerbil differ markedly, it is interesting to note the similarity of their eating behavior after lesioning of the ventromedial hypothalamus. This similarity in its own way supports the contention that certain structures in the mammalian brain are involved with similar functions across species. The maintenance of the gerbil's activity and docility after lesioning also suggests that some phenomena observed in rats with ventromedial hypothalamic lesions may not generalize well across species. It should be pointed out that the animals which exhibited the longest bout of eating during the acute dynamic phase did not necessarily show a change in day-night feeding patterns. In fact, these animals did not sustain any ventromedial hypothalamic damage and were relatively anorexic thereafter. Conversely, some of the animals with more anteromedial lesions showed nearly no large initial post-operative meal but did exhibit changes in later meal patterning. This suggests that there are two distinct anatomical loci, the destruction of which results in these two effects. This casts suspicion on the tacitly accepted view that lesions of the ventromedial

hypothalamus itself are responsible for the entire spectrum of effects associated with the "VMH syndrome."

## Bibliography

- Anand, B.K., and Brobeck, J.R.: Localization of a feeding center in the hypothalamus of the rat. Proc. Soc. Exp. Biol. Med., 24:123, 1951.
- Anand, B.K., Dua, S., and Schoenberg, K.: Hypothalamic control of food intake in cats and monkeys. J. Physiol., 127:143, 1955.
- Balagura, S., and Devenport, L.D.: Feeding patterns of normal and ventromedial hypothalamic lesioned male and female rats. J. Comp. Physiol. Psych., 71:3, 1970.
- Brobeck, J.R.: Mechanism of the development of obesity in animals with hypothalamic lesions. Physiol. Rev., 26:541, 1946.
- Brooks, C.McC.: The relative importance of changes in activity in the development of experimentally produced obesity in the rat. Amer. J. Physiol., 147:708, 1946.
- Grossman, S.P.: Aggression, avoidance and reaction to novel environments in female rats with ventromedial hypothalamic lesions. J. Comp. Physiol. Psych., 78:274, 1972.
- Joseph, S.A., and Knigge, K.M.: Effect of VMH lesions in adult and newborn guinea pigs. Neuroendocrinology, 5:309, 1968.
- Hetherington, A.W.: Non-production of hypothalamic obesity in the rat by lesions rostral or dorsal to the ventromedial hypothalamic nuclei. J. Comp. Neurol., 80:33, 1944.
- Hetherington, A.W., and Ranson, S.W.: Experimental hypothalamico-hypophyseal obesity in the rat. Proc. Soc. Exp. Biol. Med., 41:465, 1939.
- Reeves, A.G., and Plum, F.: Hyperphagia, rage and dementia accompanying a ventromedial hypothalamic neoplasm. Arch. Neurol., 20:616, 1969.

- Reynierse, J.H., Scavio, M.J, and Spanier, D.: Interaction of hunger and thirst in the Mongolian Gerbil. J. Comp. Physiol. Psych., 70:126, 1970.
- Romaniuk, A.: The effects of lesions of the medial hypothalamus on the conditioned reflexes type 2 and emotional behavior. Acta. Biol. Exp., 22:59, 1962.
- Stevenson, J.A.F., and Montemurro, D.: Experimental hypothalamic "hyperphagia" and "hypodipsia." Fed. Proc., 11:154, 1952.
- Wheatley, M.D.: Hypothalamus and affective behavior in cats: Study of effects of experimental lesions, with anatomical correlations. Arch. Neurol. Psychiat., 52:296, 1944.
- Wolf, G., and DiCara, L.: Progressive morphologic changes in electrolytic brain lesions. Exp. Neurol., 23:529, 1969.

Forwarded from Graduate School  
to Library 10/73 by nm

